

Perio-Ortho Interactions-A Review

Dr.Nadimpalli Harshita

*Department of Periodontology,Manipal college of dental sciences
Mangalore,Karnataka 575001 Manipal Academy of Higher Education*

Dr.Deepa G Kamath

*Professor and Head, Department of Periodontology,Manipal college of dental sciences
Mangalore,Karnataka 575001 Manipal Academy of Higher Education*

Dr.David Kadakampally

*Associate professor, Department of Periodontology,Manipal college of dental sciences
Mangalore,Karnataka 575001 Manipal Academy of Higher Education*

Abstract:

A multidisciplinary approach is much important to treat and avert the vast majority of the dental issues in a patient. It might be identified with various branches of dentistry. Among them orthodontics and periodontics are interrelated in various ways. The fundamental reason for the periodontal therapy is to keep up and reestablish the support of the teeth. While orthodontic treatment depends on the rule, which expresses that if prolonged pressure is applied to a tooth, tooth gets displaced from its original position as the bone around the tooth redesigns. Since the bone reaction is intervened by the periodontal ligament, tooth movement is essentially a periodontal ligament phenomenon. Common periodontal conditions which require orthodontic therapy and awareness of the pathologic changes or other undesirable changes which can happen in the periodontium because of improper orthodontic systems would help in better treatment method for administration to the patients. Orthodontic patients are highly susceptible to increased accumulation of plaque which makes integration of a periodontist very essential. This review mainly focuses on the effect of orthodontic therapy on periodontal health.

Keywords: Periodontal conditions, Orthodontic therapy, Interrelationship.

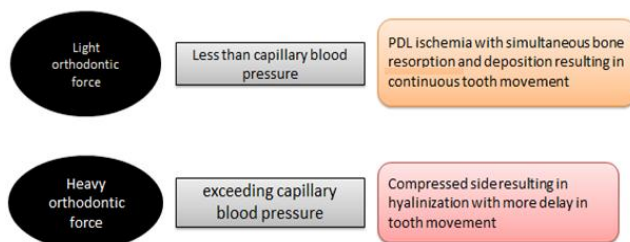
INTRODUCTION:

Orthodontic treatment is a series of processes to move poorly aligned teeth to a desirable position. These movements are strongly related to the interactions of teeth with their supportive periodontal tissues. The benefits of orthodontic treatment often go beyond the obvious physical changes of an improved bite and straighter teeth; it's also a great way to improve a person's overall self-image^[1]. Nevertheless orthodontic appliances can cause unwanted complications if adequate care is not taken during or after the therapy. This may be local or systemic, complications such as tooth discolorations, decalcification, root resorption, periodontal complications, psychological disturbances, gastrointestinal complications and allergic reactions^[2]. Among these periodontal complications are the most common and have to be taken into consideration. Therefore periodontal conditions in which orthodontic treatment is necessary should be given special importance during the interdisciplinary approach in both the ways. This review mainly focuses on the effect of orthodontic therapy on periodontal health.

EFFECT OF ORTHODONTIC FORCE ON PERIODONTAL HEALTH:

Periodontal fiber bundles are arranged such that it opposes the dislodging of the tooth from the forces during normal function. The applied force causes remodeling changes in the dental and periodontal tissues^[3].

Moreover, the literature revealed that light continuous forces (5 to 15 g) were recommended in a compromised periodontium, and the range of the commencement of tooth movement after periodontal surgery ranged from 7 days to 1 year^[4].



FACTORS TO BE CONSIDERED DURING ORTHODONTIC TREATMENT

Oral hygiene maintenance

Studies have confirmed that orthodontic treatment does not damage the periodontal attachment if the level of gingival inflammation is kept under control^{[5],[6],[7]}. However, the combination of orthodontic forces and inflammation sustained from plaque cause the uncontrolled breakdown of periodontal attachment^[8]. The presence of plaque is considered as one of the main factors in the development of gingivitis. Orthodontic brackets and elastics might interfere with effective removal of dental plaque, thereby increasing the risk of gingivitis. Few clinical studies also reported poor periodontal health and greater loss of clinical attachment level distally in the dental arches. This could be a result of poor oral hygiene in molar regions and the presence of molar bands, which favors food lodgment^[9].

Position of Brackets and Molar bands Orthodontic bands placed subgingivally may encroach on alveolar bone. The periodontal effects of banded appliances may differ from those of bonded appliances, with banding being associated with increased inflammation and loss of attachment when compared with bonding^[10]. Gingival hyperplasia can be a potential problem around orthodontic bands, leading to pseudo-pocketing^[11]. However, this usually resolves within weeks of debanding. Care must be taken to ensure that the bracket slots are perpendicular to the long axis of the tooth and not parallel to the incisal edges^[12]. If brackets placement is done based on incisal edges, greater root divergence may cause an open gingival embrasure, which is esthetically unappealing^[13].

Force Magnitude Human and animal studies agree that there is an increase in severity of root resorption with increasing force magnitude^{[14],[15]}.

Force Duration Debate exists as to whether more root resorption is associated with continuous or intermittent forces. Many believe that discontinuous forces produce less root resorption because the pause in tooth movement allows the resorbed cementum to heal^{[16],[17]}.

Gingival recession

Orthodontic treatment itself does not lead to gingival recession; it depends on the type of tooth movement. Tooth movement should be within the alveolar crest trabeculae space. Certain type of tooth movement which occurs outside bone envelope, acts as predisposing factor for gingival recession^[18].

Factors affecting gingival recession in orthodontic patients are:

Thickness of cortical plate and Type of load distribution

Thin tissue and thin cortical plate are more prone to gingival recession compared to normal or thick tissue. Various authors have reported the range of its occurrence from 1.3% to 10%^[19]. It is widely accepted that at least 2 mm of keratinized gingiva should be present to withstand orthodontic force and prevent recession. Free gingival graft can be planned in thin areas as a preventive measure^[20].

Most commonly lower anteriors are prone for gingival recession. Tipping is considered to be one of the types of force causing gingival recession by few studies, however others contradict this concept. Wennstrom et al (1987)^[21] in animal studies observed that there is no relationship between width of keratinized tissue and gingival recession occurrence during orthodontic treatment. Instead it is the buccolingual thickness which may be the determining factor for development of gingival recession and attachment loss at sites with gingivitis during orthodontic treatment. Boyd et al and Hamp et al (1992)^[22] found no differences in post orthodontic development of mucogingival problems between groups of patient who had under gone tooth extraction and those who had not. For adult orthodontic patient it is much better to prevent gingival recession than to try and correct it later. Jon Artun (2001)^[23] conducted a study to analyze whether pronounced orthodontic advancement of mandibular incisors during class II correction in mixed dentition resulted in gingival recession. They used 67 patients treated with reverse headgear. They concluded that pronounced advancement of mandibular incisors might be performed in adolescents with dentoalveolar retrusion without increasing the risk of recession.

Tooth mobility Radiographically, it can be observed that the periodontal ligament space widens during orthodontic tooth movement. Heavier the orthodontic force, greater the amount of undermining resorption expected, leading to greater mobility. If a tooth becomes extremely mobile during orthodontic treatment, all forces should be discontinued until the mobility decreases to moderate level^[24].

PERIODONTAL CONDITIONS WHICH REQUIRES ORTHODONTIC TREATMENT:

Midline diastema and correction of black triangles Adult patients previously affected by periodontal disease often present with "black triangles" due to missed interdental papillae height. By means of orthodontics, it is possible to correct teeth position and to improve soft tissue aesthetics. It was suggested that orthodontic teeth approximation might change the topography of the interproximal alveolar crest level and enhance the position of the interdental papilla^[25]. Depending on the anatomy of the patient's frenum, there may be excess fibrotic tissue in the area that will prevent space closure or cause the space to open up after it has been closed. The second condition that needs correction is when the labial frenum is positioned near the edge of the gingival tissue in a way that produces tension that without correction will lead to recession or loss of gingiva in that area^[24].

Pathological migration with infrabony defects

Patients with pathologically migrated anterior teeth could cause unaesthetic appearance to the patient which is often associated with intrabony defect. From the clinical point of view, the use of OFD to control infrabony defects before the application of

orthodontic forces was indicated in some clinical case reports^{[26],[27]}. Various orthodontic tooth movements such as intrusion, extrusion, rotation, and uprighting are needed to achieve an esthetically acceptable outcome. This helps in the control of periodontal breakdown and restoration of good oral function. Some clinical studies show that it is possible to treat deep infrabony defects with both OFD and orthodontic treatment^[28]. Intrusion is a type of tooth movement which has been recommended for teeth with horizontal bone loss or infrabony defects, provided that both the biomechanical force system and the oral hygiene are kept under control^[29]. If the oral hygiene maintenance is not proper, it might worsen the periodontal breakdown by shifting supragingival deposits into subgingival deposits. On other hand, if the tooth is supraerupted with osseous defect, intrusion and leveling of the bone defect can help to eliminate these problems. Note an osseous crater is an interproximal, two-wall defect that does not improve with orthodontic treatment^{[30],[31]}.

Tilted molars Molar uprighting may be accomplished with the use of removable or fixed orthodontic appliances. Molars are tipped mesially after prolonged loss of a tooth anterior to it in the arch. Periodontal problems often develop on the mesial aspect of the tipped tooth. Pocket depth on the mesial aspect of a mesially tipped molar will be a combination of both relative and absolute pocket formation. Some of the defect is the result of the improper relationship of the cementoamel junction to the alveolar ridge, while another portion of the defect is due to an established infrabony lesion and loss of periodontal fibers^[32]. To restore the gingival health, only initial therapy (SRP) will not be sufficient. Consultation with an orthodontist is recommended in such situations. The treatment period for molar uprighting, ranging from 3 to 6 months. When the tooth is uprighted, the mesial angular defect will widen, allowing the gingiva a more physiologic contour^[33]. Because it is believed that after molar uprighting, the periodontal defect will usually be less, due to the formation of bone when the tooth is bodily moved. At this time, routine periodontal surgery may be performed to resolve any residual periodontal defect. Osteoplasty/ostectomy with a gradual mesial sloping of the osseous defect can be used to contour the tissue in the edentulous space.

However one should pay special attention towards furcation defects, because during orthodontic treatment it can remain same or may worsen especially in the presence of inflammation (Burch et al. 1992)^[34]. Hence, initial periodontal therapy and maintenance is essential. In case of class III furcation involvement in mandibular molars, hemisection is the possible option followed by separating the roots apart by using orthodontic forces. The amount of separation is determined by the size of the adjacent edentulous spaces and the occlusion in the opposing arch. About 7 or 8 mm may be created between the roots of the hemisected molar^[35]. After the completion of orthodontic treatment, these teeth should be stabilized for at least 6 months and reassessed periodontally.

Gummy smile A 'high' smile line, also known as a 'gummy smile', is described as one having more than 2 mm of maxillary gingival display. Several conditions may result in the excessive display of gingiva, including pseudopockets caused by gingivitis, drug-induced gingival enlargement and altered passive eruption of teeth, a high lip line, a hypermobile upper lip or vertical maxillary excess^[36]. There are different possible etiologic factors for this clinical presentation, one of which is altered passive eruption. If the origin of the excessive gingival display is a skeletal abnormality, then orthognathic surgery and orthodontic treatment should be considered. If there is a dental reason for the excessive

gingival display, then correction of the gingival and osseous architecture is indicated^[37].

Gingival margin discrepancies

Uneven gingival margins can be due to various reasons like tilted tooth, short clinical crown etc.

It is necessary to evaluate four criteria to decide the type of treatment:

- 1) The relationship between the gingival margin of the maxillary central incisors and the patient's lip line.
- 2) To evaluate the labial sulcular depth over the two central incisors
- 3) To evaluate the relationship between the shortest central incisor and the adjacent lateral incisors.
- 4) Whether the incisal edges have been abraded-In such cases intrusion moves the gingival margin apically and permits restoration of the incisal edges. The intrusion should be accomplished at least 6 months before appliance removal^[38]. This allows reorientation of the principal fibers of the periodontium and avoids reextrusion of the central incisor(s) after appliance removal^[39].

PERIODONTAL SURGICAL PROCEDURE IN ORTHODONTIC PATIENT:

Periodontally accelerated osteogenic orthodontics

This technique was first introduced by Wilko et al^[40], which includes the combination of corticotomy and bone grafting. This technique is based on corticotomy facilitated tooth movement which was first described by Bryan et al in 1893 and first introduced by Kole et al^[41] in 1953. Basically it was hypothesized that cortical plates are the one which inhibits tooth movement so by disrupting the cortical plates, tooth movement can be achieved in lesser time compared to conventional treatment.

Biology underlying PAOO:

Localized areas of osteoporosis are created in the healing phase in corticotomy sites known as regional acceleratory phenomenon^{[42],[43]}. This is usually seen in fracture sites, osteotomy sites or bone grafting areas. It is not different from normal healing event except that the cell recruitment and cellular activity will be 2 to 10 folds faster than normal healing.

Timing of orthodontic treatment - placement of brackets and activation of arch wires are done 1 week prior to the surgical treatment. After the flap repositioning heavy orthodontic forces can be applied immediately and should not be delayed for more than 2 weeks after surgery. The orthodontist has a limited amount of time about 4 to 6 months to accomplish accelerated tooth movement.

PIEZOCISION:

Corticotomy combined with piezoelectric surgery was introduced in 2007 by Vercelotti and Podesta. Although they recorded a significant reduction of treatment time, this procedure was quite invasive since it required flap elevation and excessive bone removal. In 2009, Dibart et al. developed Piezocision as a minimally invasive technique, their procedure was based on small cuts in the buccal gingiva to allow the piezosurgery knife to enter and perform cuts in the buccal cortical plate to stimulate the RAP phenomenon, and it also could combine piezocision with selective tunneling when soft or hard tissue grafting is required^[44]. Piezocision was performed by making a vertical incision mesial and distal to the first molar using a microsurgical blade (IB6400, Hartzell instruments, Concord, California, USA). Then BS1 insert of the Piezotome (Satelec, Acteon group, Merignac, France) was inserted through that micro-opening to create the alveolar bone injury. The cortical bone was penetrated to a depth of 0.5mm mesially and distally (decortications) for which low-frequency ultrasonic waves (28–36kHz) are used. Under these conditions, the microvibrations that were created in the

piezoelectric handpiece caused the inserts to vibrate linearly between 30 and 60 μm . Recently it has been shown that a similar RAP effect is produced when decortications are done with the piezotome. Looking at the current literature, once the bone has demineralized following bur corticotomy, there is a three to four months window of opportunity to move teeth rapidly through the demineralized bone matrix before the alveolar bone remineralizes^[45]. The effect of Piezocision on the length of this window of opportunity is being investigated. Clinical reports indicate that this RAP could last up to 6 months.

Nelson et al in 1983^[46] stated that it can be repeated more than once in the same area to re-activate the RAP (after 5-6 months) and keep the area demineralized (depending on the difficulty of the movements being performed and the morphology of the patient's bone). The repeated procedure takes very little time and is so conservative that it meets high patient's acceptance yet yielding great treatment outcomes.

CONCLUSION:

Periodontal health is important for every type of dental treatment, specifically for orthodontic treatment. Orthodontic treatment has its positive and negative effects on periodontium. Over past few decades adult patients are seeking orthodontic treatment for esthetic purposes. In such situations combined periodontal and orthodontic treatment can be beneficial to the patients. Orthodontic treatment should not be performed in periodontitis which is in its active stage, so regular checkup for the evaluation of periodontal parameters is necessary. For the success of treatment, one of the main factors is maintenance of periodontium in healthy condition, good oral hygiene maintenance and regular follow-up which would be required for achieving expected outcome. But there is no conclusive evidence in few aspects of this interdisciplinary approach due to inadequate epidemiologic studies with adequate comparison groups and follow-up time are lacking.

REFERENCES

1. C. T. Preoteasa, E. Ionescu, and E. Preoteasa, Risks and Complications Associated with Orthodontic Treatment, 2012.
2. N. F. Talic, "Adverse effects of orthodontic treatment: a clinical perspective," Saudi Dental Journal, vol. 23, no. 2, pp. 55–59, 2011.
3. Vinod K, Reddy YG, Reddy VP, Nandan H, Sharma M. Orthodonticperiodontics interdisciplinary approach. J Indian Soc Periodontol 2012;16:11-5.
4. Meeran NA. Cellular response within the periodontal ligament on application of orthodontic forces. J Indian Soc Periodontol 2013;17:16-20.
5. Ericsson I, Thilander B. Orthodontic forces and recurrence of periodontal disease: An experimental study in the dog. Am J Orthod 1978;74:41-50.
6. Ericsson I, Thilander B. Orthodontic relapse in dentitions with reduced periodontal support: An experimental study in dogs. Eur J Orthod 1980;2:51-7.
7. Ericsson I, Thilander B, Lindhe J. Periodontal conditions after orthodontic tooth movements in the dog. Angle Orthod 1978;48:210-8.
8. Ericsson I, Thilander B, Lindhe J, Okamoto H. The effect of orthodontic tilting movements on the periodontal tissues of infected and non-infected dentitions in dogs. J Clin Periodontol 1977;4:278-93.
9. Zachrisson BU, Zachrisson S. Gingival condition associated with partial orthodontic treatment. Acta Odontol Scand 1972;30:127-36.
10. Boyd RL, Baumrind S. Periodontal considerations in the use of bonds or bands on molars in adolescents and adults. Angle Orthod 1992;62:117-26. S.
11. A. Alexander, "Effects of orthodontic attachments on the gingival health of permanent second molars," The American Journal of Orthodontics and Dentofacial Orthopedics, vol. 100, no. 4, pp. 337–340, 1991
12. O. Malmgren, L. Goldson, C. Hill, A. Orwin, L. Petrini, and M. Lundberg, "Root resorption after orthodontic treatment of traumatized teeth," The American Journal of Orthodontics, vol. 82, no. 6, pp. 487–491, 1982.
13. M. Mavragani, A. Vergari, N. J. Selliseth, O. E. Boe, and P. J. Wisth, "A radiographic comparison of apical root resorption after orthodontic treatment with a standard edgewise and a straight-wire edgewise technique," European Journal of Orthodontics, vol. 22, no. 6, pp. 665–674, 2000.
14. A. D. Vardimon, T. M. Graber, L. R. Voss, and J. Lenke, "Determinants controlling iatrogenic external root resorption and repair during and after palatal expansion," Angle Orthodontist, vol. 61, no. 2, pp. 113–122, 1991.
15. G. J. King and W. Fischlschweiger, "The effect of force magnitude on extractable bone resorptive activity and cemental cratering in orthodontic tooth movement," Journal of Dental Research, vol. 61, no. 6, pp. 775–779, 1982.

16. K. Reitan, "Effects of force magnitude and direction of tooth movement on different alveolar bone types," *The Angle Orthodontist*, vol. 34, no. 4, pp. 244-255, 1964.
17. E. Levander, O. Malmgren, and S. Eliasson, "Evaluation of root resorption in relation to two orthodontic treatment regimes. A clinical experimental study," *European Journal of Orthodontics*, vol. 16, no. 3, pp. 223-228, 1994.
18. Wennstrom, J.L. (1990). The significance of the width and thickness of the gingiva in orthodontic treatment. *Deutsche Zahnärztliche Zeitschrift* 45, 136-141.
19. Geiger AM. Mucogingival problems and the movement of mandibular incisors-a clinical review. *Am J Orthod* 1980;511-27.
20. Carranza F.A and Newman, M.G. (1996); *Clinical Periodontology*, 9th Edn. W.B. Saunders and Co., Philadelphia.
21. Wennstrom, J.L., Lindhe, J., Sinclair, F. & Thilander, B. (1987). Some periodontal tissue reactions to orthodontic tooth movement in monkeys. *Journal of Clinical Periodontology* 14,121-129.
22. Artun, J. & Urbye, K.S. (1988). The effect of orthodontic treatment on periodontal bone support in patients with advanced loss of marginal periodontium. *American Journal of Orthodontics* 93, 143-148
23. Boyd, R.L. & Baumrind, S. (1992). Periodontal considerations in the use of bands or bands on molars in adolescents and adults. *The Angle Orthodontist* 62,117-126. .
24. Lindhe J., Karring T and Lang N.P. (1997): *Clinical Periodontology and implant dentistry*, 3rd Edn. Munksgaard, Copenhagen.
25. Kokich V.G. Esthetics: the orthodontic-periodontic restorative connection. *Semin Orthod* 1996; 2: 21-30
26. Corrente G, Abundo R, Re S, Cardaropoli D, Cardaropoli G. Orthodontic movement into infrabony defects in patients with advanced periodontal disease: A clinical and radiological study. *J Periodontol* 2003;74:1104-1109.
27. Cirelli JA, Cirelli CC, Holzhausen M, Martins LP, Brandao CH. Combined periodontal, orthodontic, and restorative treatment of pathologic migration of anterior teeth. A case report. *Int J Periodontics Restorative Dent* 2006;26:501-506.
28. Cardaropoli D, Re S, Corrente G, Abundo R. Reconstruction of the maxillary midline papilla following a combined orthodontic-periodontic treatment in adult periodontal patients. *J Clin Periodontol* 2004;31: 79-84.
29. Berglundh, T., Marinello, C.P., Lindhe, J., Thilander, B. & Liljenberg, B. (1991). Periodontal tissue reactions to orthodontic extrusion. An experimental study in the dog. *Journal of Clinical Periodontology* 18, 330-336.
30. Ochsenein C, Ross S: A re-evaluation of osseous surgery. *Dent Clin North Am* 1969; 13:87.
31. Schluger S: Osseous resection: A basic principle in periodontal surgery. *Oral Surg* 1949; 2:316.
32. Jin, L.J. & Car, C.F. (1992). Clinical diagnosis of trauma from occlusion and its relation with severity of periodontitis. *Journal of Clinical Periodontology* 19, 92-97.
33. Bagga DK. Adult orthodontics versus adolescent orthodontics: An overview. *J Oral Health Comm Dent* 2010;4:42-7.
34. Burch, J.G., Bagci, B., Sabulski, D. & Landrum, C. (1992). Periodontal changes in furcations resulting from orthodontic uprighting of mandibular molars. *Quintessence International* 23, 509-513.
35. Muller, H-P, Eger, T. & Lange, D.E. (1995). Management of furcation-involved teeth. A retrospective analysis. *Journal of Clinical Periodontology* 22, 911-917.
36. Hunt O, Johnston C, Hepper P, Burden D, Stevenson M. The influence of maxillary gingival exposure on dental attractiveness ratings. *Eur J Orthod*. 2002;24:199-204.
37. Sugawara J, Daimaruya T, Umemori M, Nagasaka H, Takahashi I, Kawamura H, Mitani H. Distal movement of mandibular molars in adult patients with skeletal anchorage system. *Am J Orthod Dentofacial Orthop*. 2004;125: 130-138.
38. Kokich V: Esthetics and vertical tooth position: The orthodontic possibilities. *Compendium Cont Ed Dent* 1997; 18:1225.
39. Kokich V: Esthetics: The orthodontic-periodontic-restorative connection. *Semin Orthod* 1996; 2:21.
40. Lang, N.P. (1977). Das präprotetische Aufrichten von gekippten unteren Molaren im Hinblick auf den parodontalen Zustand. *Schweizerische Monatschrift für Zahnheilkunde* 87, 560-569.
41. Wilcko WM, Wilcko MT, Bouquot JE. Rapid orthodontics with 3. alveolar reshaping: two case reports of decrowding. *Int J Periodontics Restorative Dent*. 2001;21:9-19.
42. Kole H. Surgical operation on the alveolar ridge to correct occlusal 5. abnormalities. *Oral Surg Oral Med Oral Pathol*. 1959;12:515-29 concl.
43. Schilling T, Müller M, Minne HW, Ziegler R. Influence of inflammation-mediated osteopenia on the regional acceleratory phenomenon and the systemic acceleratory phenomenon during healing of a bone defect in the rat. *Calcif Tissue Int*. 1998;63:160-6.
44. Dibart, S., Sebaoun, J.D., Surmenian, J. Piezocision: a minimally invasive, periodontally accelerated orthodontic tooth movement procedure. *Compendium of Continuing Education in Dentistry* 2009; 30:342-350.
45. Lee, W., Karapetyan, G., Moats, R., et al. Corticotomy-/Osteotomy-assisted Tooth Movement microCTs Differ. *Journal of Dental Research* 2008;87(9):861-865
46. Nelson D and Dibart S. Successfully Solving an Orthodontic Challenge with Piezocision: A Case Report. *Journal of Clinical Orthodontics* 2014(in press)