

Prevalence of Perforations in RCTs and Knowledge of Management among Under-Graduate Students

Prema Sivakumar*

Undergraduate Student, Saveetha Dental College

Dr. Dhanraj

HOD, Department of Prosthodontics, Saveetha Dental College

Abstract

Root canal perforations are an artificial communication between the root canal system and the periodontium. They aren't uncommon in endodontic practice, however, the success of the treatment depends on the timely diagnosis and management of the same. This study was aimed at evaluating the prevalence of perforations in RCT among undergraduate students and their knowledge on management of the same. An online questionnaire-based survey was conducted among 118 undergraduate students from and freshly graduated interns from Saveetha Dental College and the results were obtained. 61% of the students have encountered perforations in their Clinical practice at the Saveetha Undergraduate clinic or in their private practice. We found that the general awareness on management of perforations and the need to repair perforations was quite good.

Keywords: Root canal treatment, Perforations, MTA, Perforation repair, iatrogenic

INTRODUCTION

Perforations are a connection, from the tooth structure to it's surrounding structures(periodontium), which may be created during or after a root canal treatment (iatrogenic) while attempting entry into the root canal system or as a factor of a biological process, where-in, there is a formation of a pathological connection, due to extensive caries, external/internal-resorption etc. [1] It can occur due to lack of knowledge from the part of the dentist, of the dental anatomy(inclination of the tooth and it's position in the dental arch), or due to calcifications in pulp chambers, misidentification of the root-canal, incorrect arch inclination like rotation or tipping, posts, crowns or use of inappropriate instruments.[2] The various factors affecting the successful management of the same are the location, size, time of repair, periodontal status of the tooth, access to repair, and the biocompatibility of the perforation repair material.[3] There are various methods of diagnosing a perforation, in endodontic practice. It is usually centered around symptoms and Radiographic evaluations. The patient may experience a variety of symptoms ranging from sensitivity to pain, and bleeding on introducing the instrument into the canal.[4] Various methods of assessing and evaluating a perforation include direct visual evaluation, Paper points for bleeding, Electronic apex locators, symptomatic findings, DOMs(Dental Operating Microscopes), CBCT (Cone Beam Computed Tomography), Radiographs, Dental loupes for magnification. The various methods that can be employed by the practitioner to minimize the incidence of perforations are, the use of NiTi files, Anti-curvature filing, using the various diagnostic techniques mentioned above during the treatment to intervene and avoid any perforations at all, and also the use of non-end cutting burs.

The various types of iatrogenic perforations that can occur during root-canal treatments can occur during the access cavity preparation (gouging- cervical perforations), and during negotiation of the root canal for biomechanical

preparation (zipping, strip perforation, canal transportation) or even during post-space preparation. These will ultimately lead to the failure of the root canal treatment. [5]

A small sized perforation, in the root, apical to the crestal bone and epithelial attachment, that is sealed immediately has a better prognosis.[5] The various materials that can be used in the repair of the perforation are MTA, Calcium hydroxide, Calcium silicates,[6] dentin chips, GIC and less commonly, or rather historically, silver amalgam, cavit, Indium foil, Aluminium foil, Zinc-Oxide Eugenol, Plaster of Paris. These materials aid in sealing off the connection and promote osteogenesis and cementogenesis.[7,8,9]

In the event of a perforation, during treatment, the patient should be informed of the same, the risks and prognosis be explained and the subsequent procedures are to be explained.[10]

In the event of not detecting the perforation or not addressing the perforation, it leads to an inflammatory response of the periodontium which may or may not be due to bacterial contamination, and may lead to destruction of periodontal tissue and alveolar bone, pocket formation, fistula formation, proliferation of tissue leading to granuloma formation, and ultimately the loss of the tooth.[11]

MATERIALS AND METHODS

This cross-sectional survey-based study was conducted to assess the level of awareness about perforations, their prevention, diagnosis and management amongst (Inclusion Criteria) Undergraduate students belonging to the years 3, 4 and 5 of Saveetha Dental college pertaining to the cases they treated from the OP and freshly passed out graduates who are practicing dentists. Of the sample size, 8% were 3rd years, 32% were 4th years, 44% were 5th years (interns), and 16% were recently passed out practicing dentists. Informed consent was obtained and the nature of the study was explained to the participants. The study was

conducted on the online survey tool “Survey Planet” and was circulated to 118 students and dentists. 12 close-ended questions were asked including the name, qualification, and other questions, listed below, regarding perforations in their dental practice. These questions had pre-meditated options or choices for the participants to select, and in a few questions, they could choose multiple options.

- Have you encountered perforations in your clinical practice?
- Which tooth?
- Is it solely iatrogenic?
- Are you aware of the Danger Zone?
- Which is the Danger Zone in mandibular molars?
- Cervical perforations are also called?
- How can you potentially minimize perforations? (can select multiple options)
- Why should perforations be repaired?
- What materials are best used to repair perforations? (can select multiple options)

The raw data from the site was assimilated onto an Excel spreadsheet and a statistical analysis of the same was done on excel, and graphs were made.

RESULTS

61% of the participating dentists had encountered perforations in their dental practice. The tooth that was most commonly perforated, was lower molars, followed by lower pre-molars and upper-anteriors, and lower-anteriors. (Fig. 1) and 57% of the study population believed that perforations are solely iatrogenic. 70 % of the study population was aware of the danger zone. In relation to the lower molars the danger zone is the distal surface of the mesial root. 27% of the people that answered (this was an optional question and only 105 out of 118 had answered), had chosen the right answer (distal surface of mesial root) 29.5% of the people had chosen the wrong answer (mesial surface of mesial root) (Fig. 2). Only 20% of the study population was aware that cervical perforations are also called gouging, the rest of them chose incorrect answers (47% - strip perforation, 25%- zip perforation, 8%- canal transportation) (Fig.3) On minimizing perforations, the participants were given the option to pick as many options as they wanted as, all were right answers. The most picked options in the order of preference were: Electronic apex locators, NiTi files, RVG (RadioVisioGraphy), anti-curvature filing, Non-end cutting bur, Dental Operating Microscopes. (Fig. 4) The next question was, why perforations have to be repaired (All the options were right, but the last option was all of the above) 62% of the study population answered this right. (Fig. 5) The last question was about the materials, that are best used to repair perforations. (multiple options could be chosen), the most chosen options in that order respectively are: MTA (Mineral Trioxide Aggregate) 58%, Zinc Oxide Eugenol 19%, Dentin chips 12%, Indium foil 6%, Plaster of Paris 3%, Aluminium foil 2%. (Fig. 6)

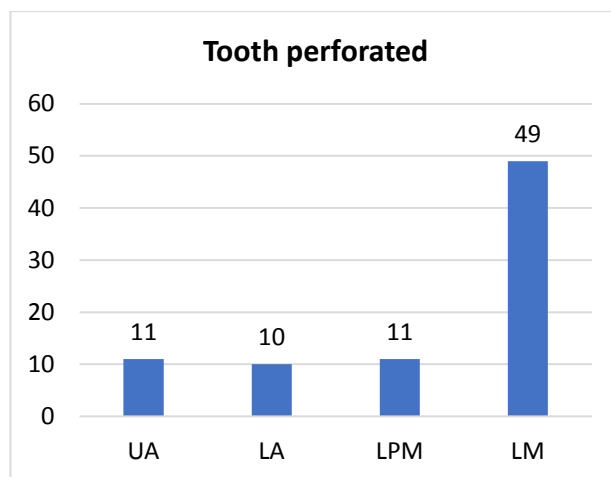


Fig. 1 : Incidence of perforations in teeth LM: lower molars, LPM : Lower premolar, LA: Lower anterior, UA, Upper anterior.

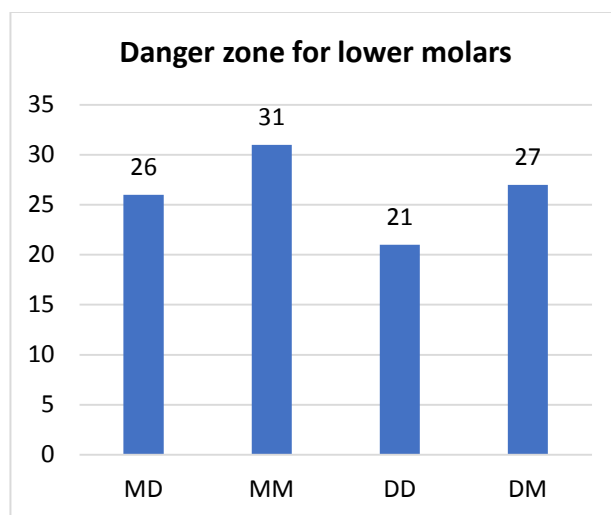


Fig. 2: Danger zone for the lower molars. DM: Distal surface of mesial root, DD: Distal surface of distal root, MM: Mesial surface of mesial root, MD: Mesial surface of distal root.

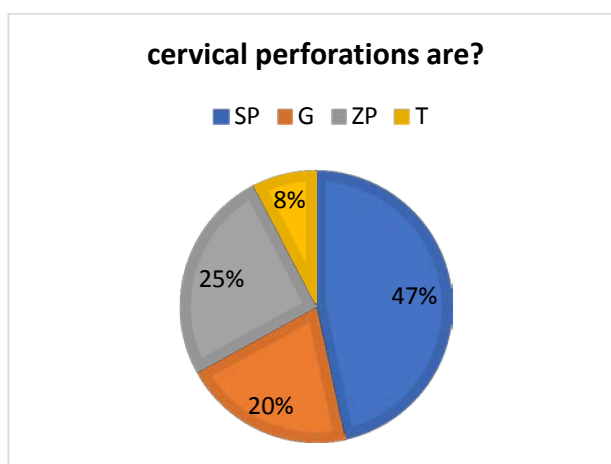


Fig. 3: Cervical perforations are also called. SP: Strip perforations, G: Gouging, ZP: Zip perforations, T: Transportation.

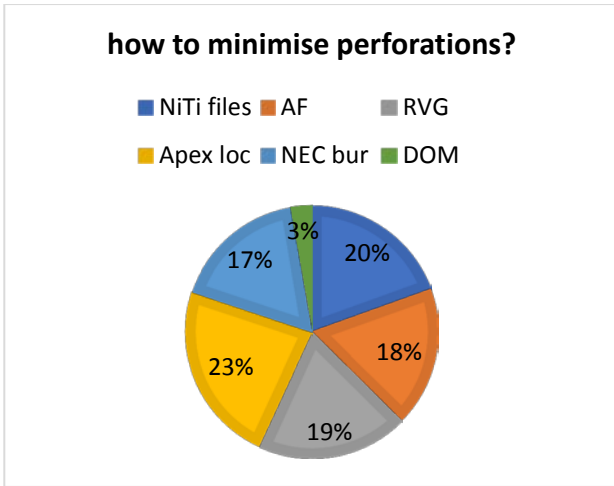


Fig. 4: Methods of minimizing perforations. AF- Anti-curvature filing, RVG-Radiovisiography, Apex loc- Electronic apex locators, NEC – Non end cutting bur, DOM- Dental Operating Microscopes.

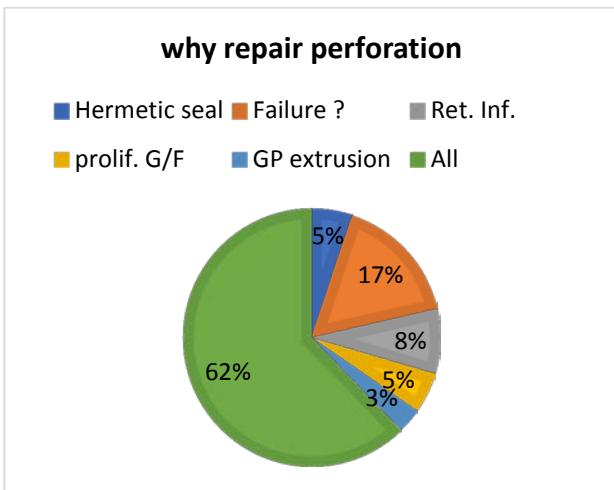


Fig. 5: Why repair perforations. Ret. Inf: Retrograde infection, Prolif. G/F : proliferation of gingival/furcal tissue.

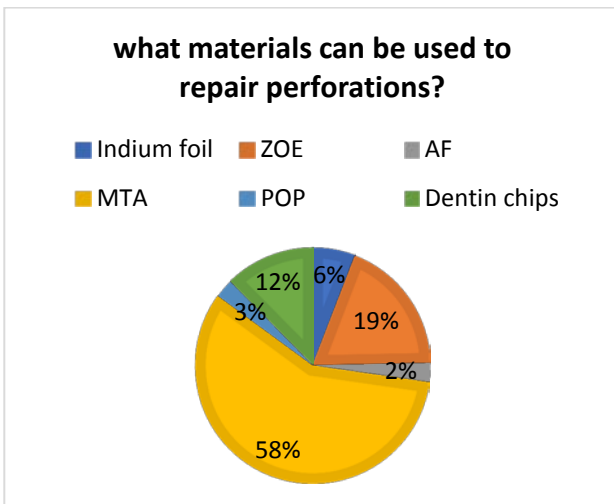


Fig. 6: materials to repair perforations. ZOE- Zinc-Oxide Eugenol, AF- Aluminium Foil, MTA- Mineral Trioxide Aggregate, POP- Plaster Of Paris.

DISCUSSION

Preservation of the natural dentition, to the best possible extent, is essential for maintaining the function and esthetics. Endodontic care is indispensable in maintaining general dental health. Perforations in endodontic treatments are the second greatest cause for failure of the root canal treatment.[12,13,14] They are not always iatrogenic and can also be pathological contrary to the popular belief in our study population. The repair of perforations can be done in a surgical or a non-surgical way, depending on the site and size of the perforation, but either way, the repair of the perforation and sealing it is a mandate to avoid leakage of irritants from within the root canal that will further worsen the inflammatory reaction in the periodontium.[15] When the perforation is small, accessible and the surrounding periodontium is healthy without infection, non-surgical repair can be carried out. Cases where non-surgical treatment is refractory or where the inflammation in the periodontium has to be addressed, surgical intervention is required. [3] The failure to diagnose and treat a perforation in time can lead to a damaging sequel of events that results in the loss of the tooth. Perforation repair is also important to maintain a hermetic seal, preventing failure of the root canal treatment, retrograde infection, proliferation of gingival or furcal tissue, GP extrusion, which are few of the many reasons to repair perforations. Most of the study population wasn't aware of the fact that the danger zone in the mandibular molars is the distal surface of the mesial roots, and due to the thin dentin in that region, it often results in perforations, and this can be prevented by anti-curvature filing. The various other methods to minimize the incidence of and diagnose perforations in time are Clinical knowledge, the know-how on identifying a perforation when they see one, (it is usually characterized by excessive bleeding, during cleaning and shaping, or sudden pain), knowledge on the internal anatomy, assessing radiographs, using non-end cutting burs, use of electronic apex locators, respecting the working length an not violating the same, use of NiTi files, anti-curvature filing, Dental Operating Microscopes for magnification, and ease of working. The prognosis of the perforation repair depends greatly on the location, size and time of perforation repair, earlier the better.[16] Perforations in the furcal areas or the cervical third of the root have a poorer prognosis, as they usually trigger inflammatory reactions.[7] Depending on the tooth that is perforated, and the site on the particular tooth, an esthetic challenge may be posed, especially in the upper anteriors.[17] The most popular answer to the question, about the appropriate material to repair perforations was MTA. Various materials like tin foil, paraffin, gutta percha, dentin chips, calcium hydroxide, GIC, Zinc Phosphate, ZOE cements, EBA cements, gold foil, indium foil, gel foam, and more recently, MTA, Biodentine, Endo-sequence, Bio aggregate have been used for the repair of perforations. The choice of material is crucial as it will be in intimate contact with the tooth and the periodontium, and can make or break the success of the treatment, amongst other factors.[18] MTA is currently one of the most widely used cements for

perforation repair.[19,20,21,22] MTA is well tolerated and is biocompatible, induces a favorable response in the periodontal tissues[23], and stimulates mineral deposition in the material-dentin interface and the dentinal tubules.[24] But a downside is they can't be used in areas where there is a risk of dissolution.

The study could be conducted in a larger sample size spanning a better variety of dentists, to have a more accurate analysis. The practitioner' knowledge and expertise on the assessment of radiographs, tooth morphology, root curvature, and materials that are to be used for the repair are extremely crucial in the success of perforation repair or avoiding it in the first place.

CONCLUSION

Perforations aren't an uncommon occurrence in clinical practice and in my opinion, the failure to diagnose or manage a perforation are more perilous to the outcome of the treatment when compared to the incidence of a perforation. With the advent of so many new technologies, the assessment, evaluation and treatment of the same isn't a difficult task. From the study, it can be concluded, that though most of the study population didn't have sufficient knowledge about the technicalities or terminologies, most of them well aware about the need to repair a perforation, how to minimize it and the choice of material for a successful repair.

REFERENCES

1. Tsesis I, Fuss Z. Diagnosis and treatment of accidental root perforations. *Endod Topics*. 2006; 13:95-107.
2. Arens DE, Torabinejad M. Repair of furcal perforation with mineral trioxide aggregate : two case reports. *Oral Surg Oral Med Oral Pathol Oral Radiol Endod*. 1996; 82(1):84-8.
3. Fuss Z, Trope M. Root perforations: classification and treatment choices based on prognostic factors. *Dental Traumatology*. 1996; 12(6):255-64.
4. Alhadainy HA. Root Perforations: A review of literature *Oral Surg Oral Med Oral Pathol*. 1994; 78:368-74.
5. Estrela C, Pécora JD, Estrela CRA, Guedes OA, Silva BS, Soares CJ et al. Common operative procedural errors and clinical factors associated with root canal treatment. *Braz Dent J*. 2017 JanApr;28(2):179-90. <https://doi.org/10.1590/0103-6440201702451>
6. Carlos ESTRELA et al. Root perforations: a review of diagnosis, prognosis and materials. *Braz. Oral Res*. Jun. 2018;32(suppl):e73. <https://doi.org/10.1590/1807-3107bor-2018.vol32.0073>
7. Cogo DM, Vanni JR, Reginatto T, Fornari V, Baratto Filho F. Materiais utilizados no tratamento das perfurações endodônticas. *Rev Sul-Bras Odontol*. 2009;6:195-203.
8. Juarez Broon N, Bramante CM, de Assis GF, Bortoluzzi EA, Bernardineli N, de Moraes IG, et al. Healing of root perforations treated with mineral trioxide aggregate (MTA) and Portland cement. *J Appl Oral Sci*. 2006;14:305-11.
9. Silva Neto UX, Moraes IG. Capacidade seladora proporcionada por alguns materiais utilizados em perfurações na região de furca de molares humanos extraídos. *J Appl Oral Sci*. 2003;11:27-33.
10. Estrela C, Biffi JC, Moura MS, Lopes HP. Treatment of endodontic failure. In: Estrela C. *Endodontic Science*. 2nd ed. São Paulo: Artes Médicas; 2009. p. 917-52.
11. Touré B, Faye B, Kane AW, Lo CM, Niang B, Boucher Y. Analysis of reasons for extraction of endodontically treated teeth: a prospective study. *J Endod*. 2011 Nov; 37(11):1512-5. <https://doi.org/10.1016/j.joen.2011.07.002>
12. Seltzer S. *Endodontology: biologic considerations in endodontic procedures*. 2nd ed. Philadelphia: Lea & Fabiger; 1988. Repair following root canal therapy; p. 389-438.
13. Holland R, Otobani Filho JA, Souza V, Nery MJ, Bernabé PF, Dezan Junior E. Mineral trioxide aggregate repair of lateral root perforations. *J Endod*. 2001 Apr;27(4):281-4. <https://doi.org/10.1097/00004770-200104000-00011>
14. Bakland LK. Endodontic mishaps: Perforations. *J Calif Dent Assoc*. 1991; 19:41-4.
15. Breault LG, Fowler EB, Primack CPD. Endodontic Perforation Repair with Resin-Ionomer: A Case Report. *J Contmp Dent Prac*. 2000; 1(4):1-7.
16. Ng YL, Mann V, Gulabivala K. A prospective study of the factors affecting outcomes of nonsurgical root canal treatment: part 1: periapical health. *Int Endod J*. 2011; 44:583-609.
17. de Chevigny C, Dao TT, Basrani BR. Treatment outcome in endodontics: the Toronto study-phases 3 and 4: orthograde retreatment. *J Endod*. 2008; 34:131-137.
18. Jeevani E, Jayaprakash T, Bolla N, Vemuri S, Sunil CR. Evaluation of sealing ability of MM-MTA, Endosequence, and biodentine as furcation repair materials: UV spectrophotometric analysis. *Journal of Conservative Dentistry*. 2014; 17:340-3.
19. Parirokh M, Torabinejad M. Mineral trioxide aggregate: a comprehensive literature review—Part I: chemical, physical, and antibacterial properties. *J Endod*. 2010 Jan;36(1):16-27. <https://doi.org/10.1016/j.joen.2009.09.006>
20. Torabinejad M, Parirokh M. Mineral trioxide aggregate: a comprehensive literature review—part II: leakage and biocompatibility investigations. *J Endod*. 2010 Feb;36(2):190-202. <https://doi.org/10.1016/j.joen.2009.09.010>
21. Parirokh M, Torabinejad M. Mineral trioxide aggregate: a comprehensive literature review—Part III: Clinical applications, drawbacks, and mechanism of action. *J Endod*. 2010 Mar;36(3):400-13. <https://doi.org/10.1016/j.joen.2009.09.009>
22. Komabayashi T, Spångberg LS. Particle size and shape analysis of MTA finer fractions using Portland cement. *J Endod*. 2008 Jun;34(6):709-11. <https://doi.org/10.1016/j.joen.2008.02.043>
23. Camilleri J, Pitt Ford TR. Mineral trioxide aggregate: a review of the constituents and biological properties of the material. *Int Endod J*. 2006;39:747-54.
24. Dreger LA, Felipe WT, Reyes-Carmona JF, Felipe GS, Bortoluzzi EA, Felipe MC. Mineral trioxide aggregate and Portland cement promote biomineralization in vivo. *J Endod*. 2012;38:324-9.